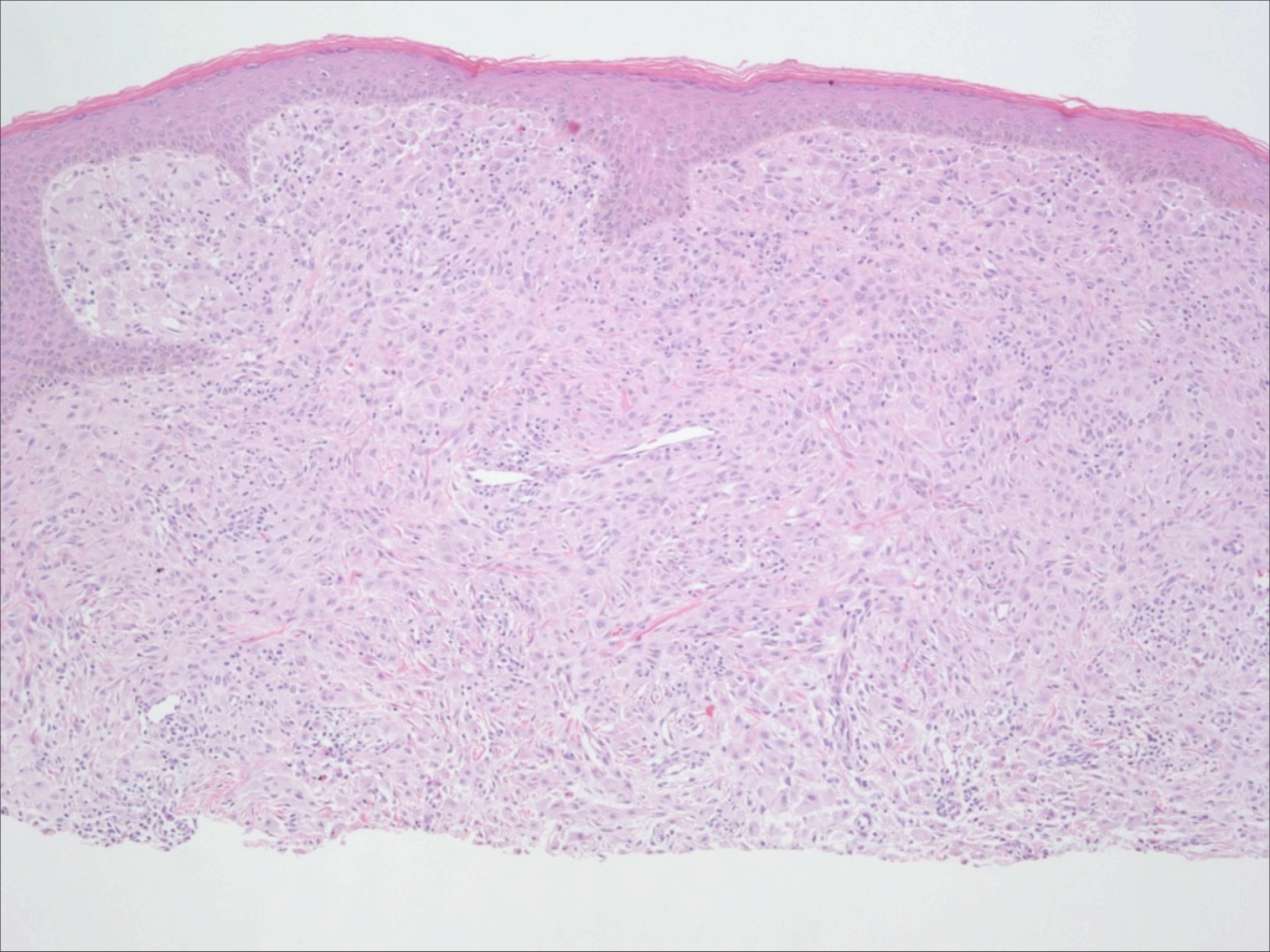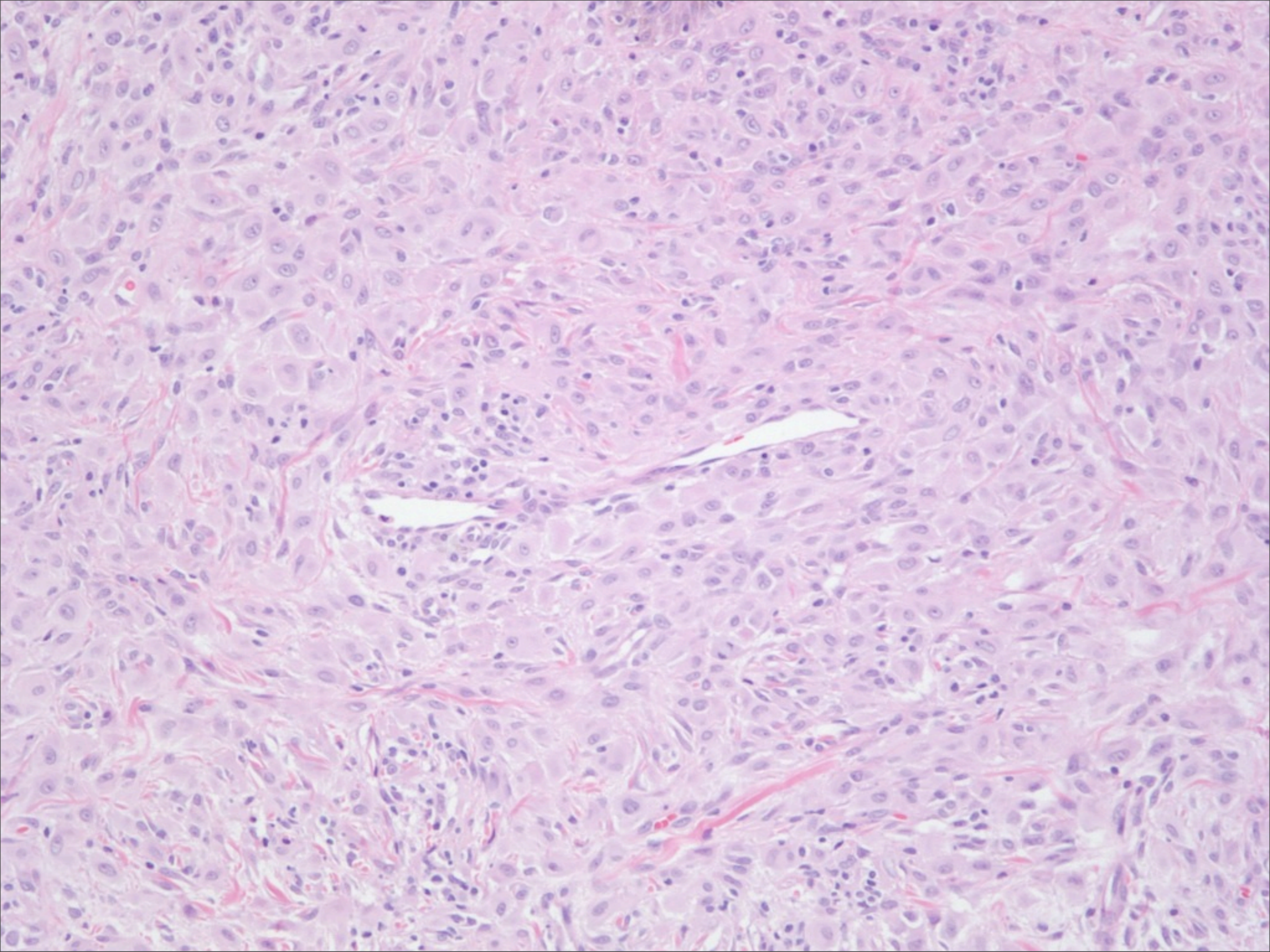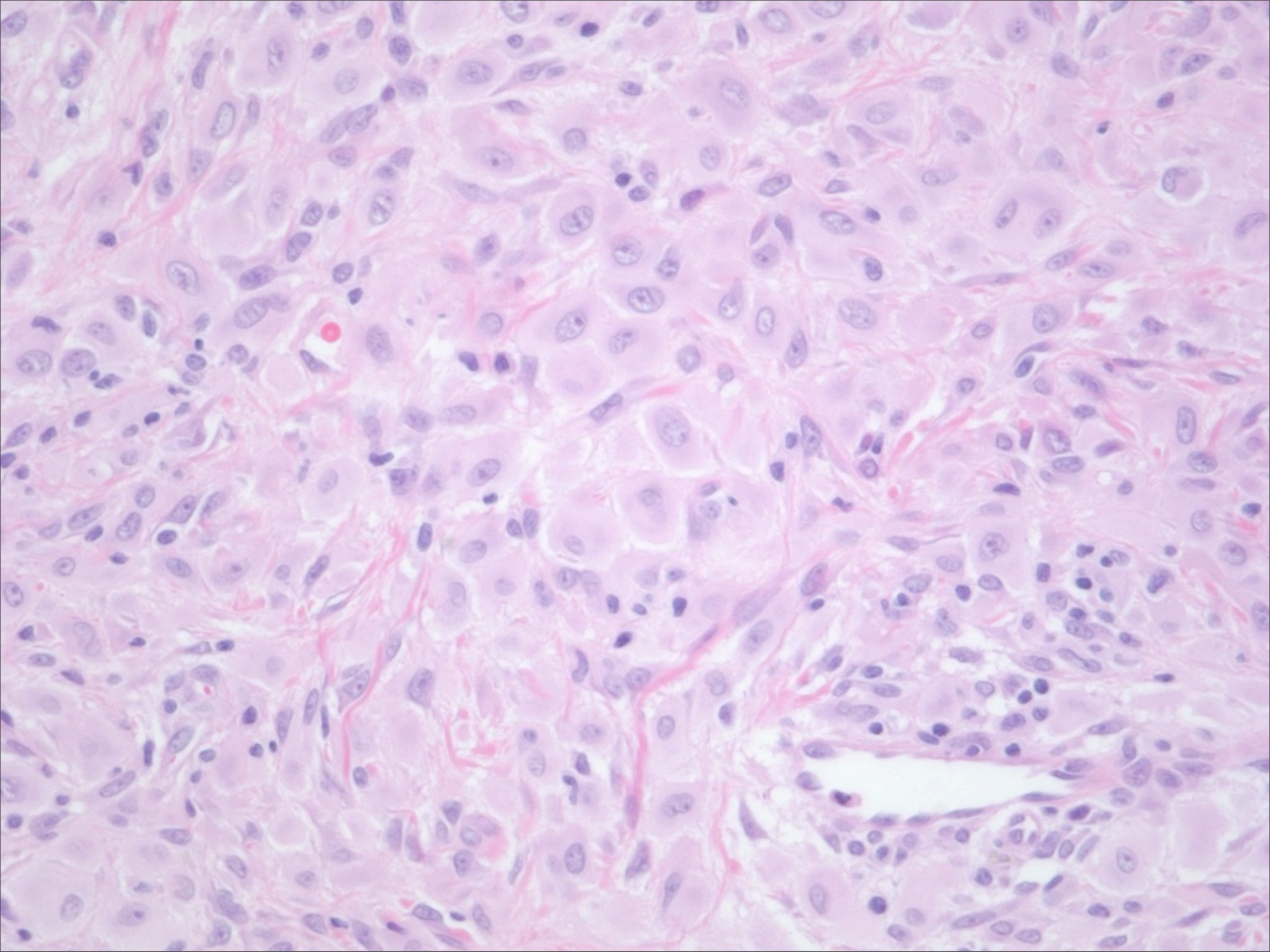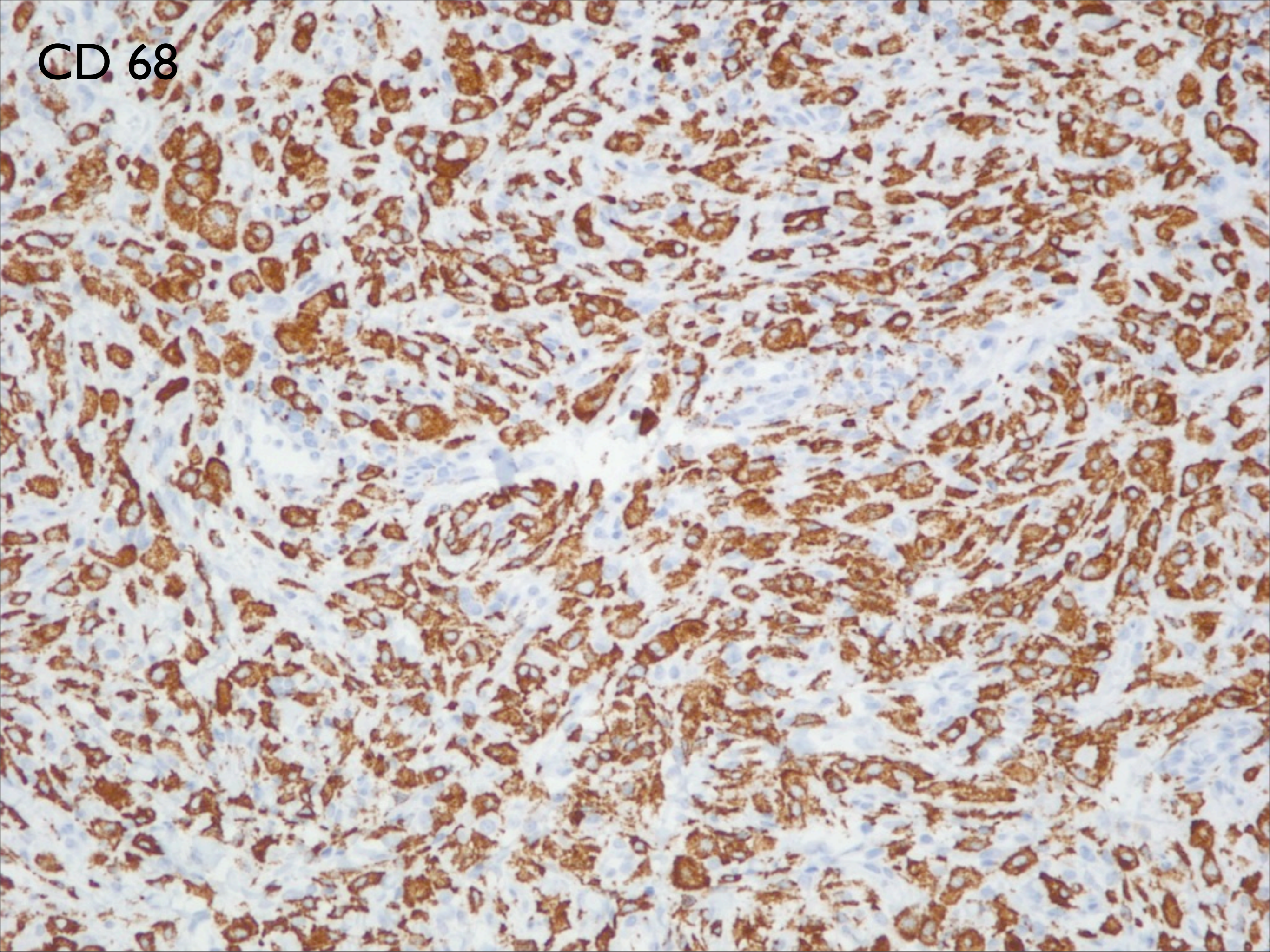
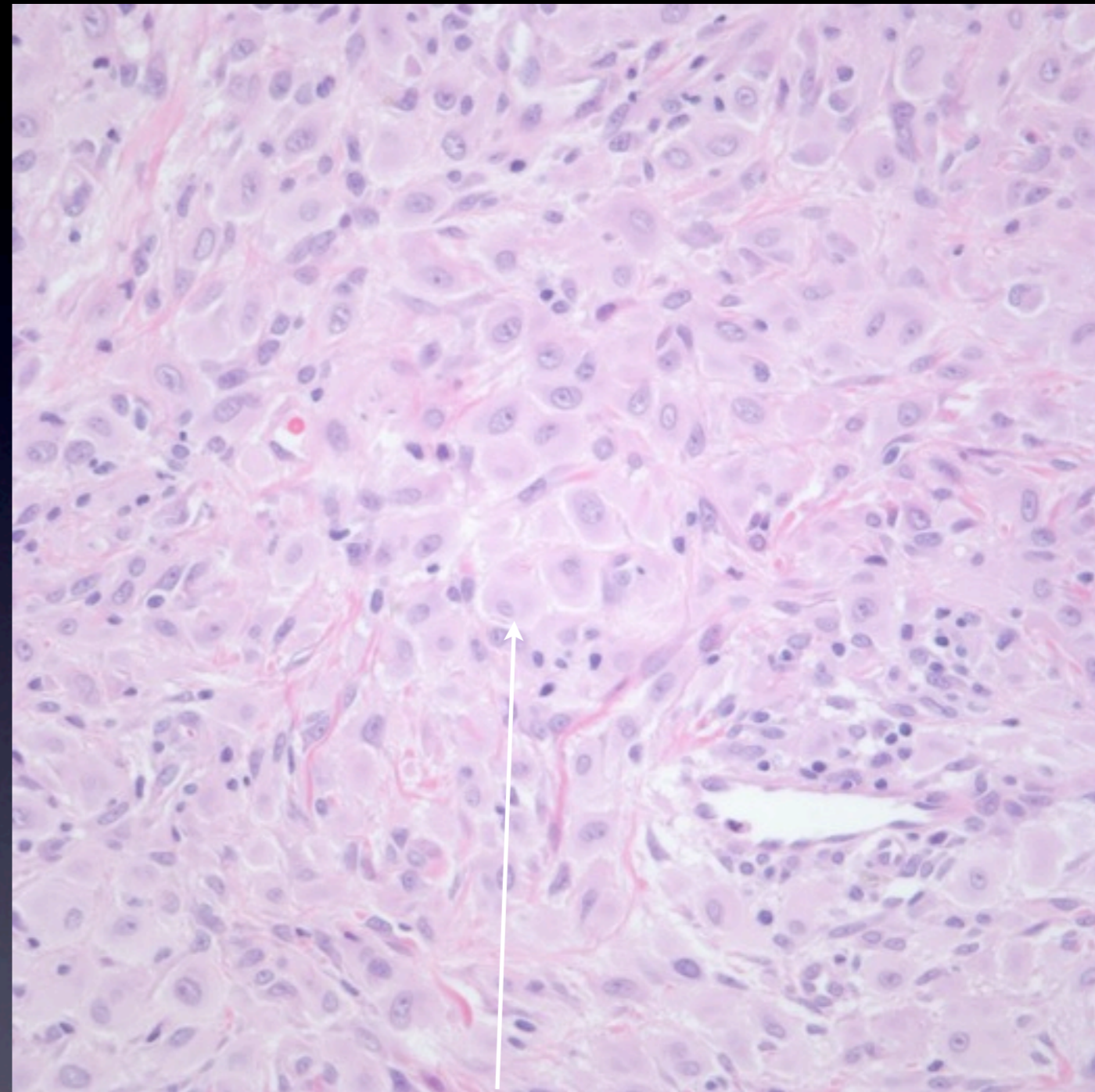
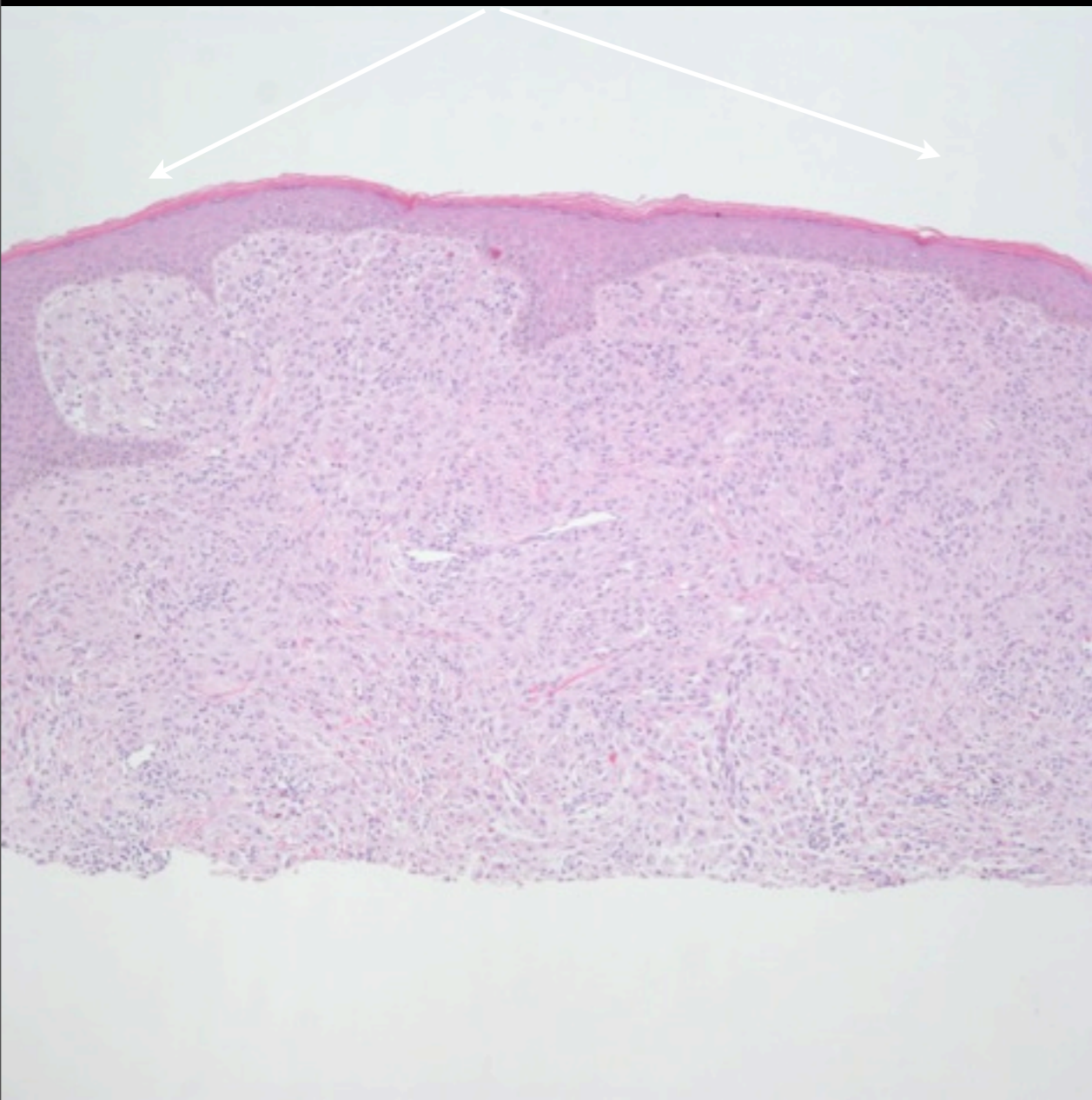


CD 68



# Reticulohistiocytoma

# Circumscribed dermal tumor



Histiocytes with Eosinophilic  
Ground Glass Cytoplasm